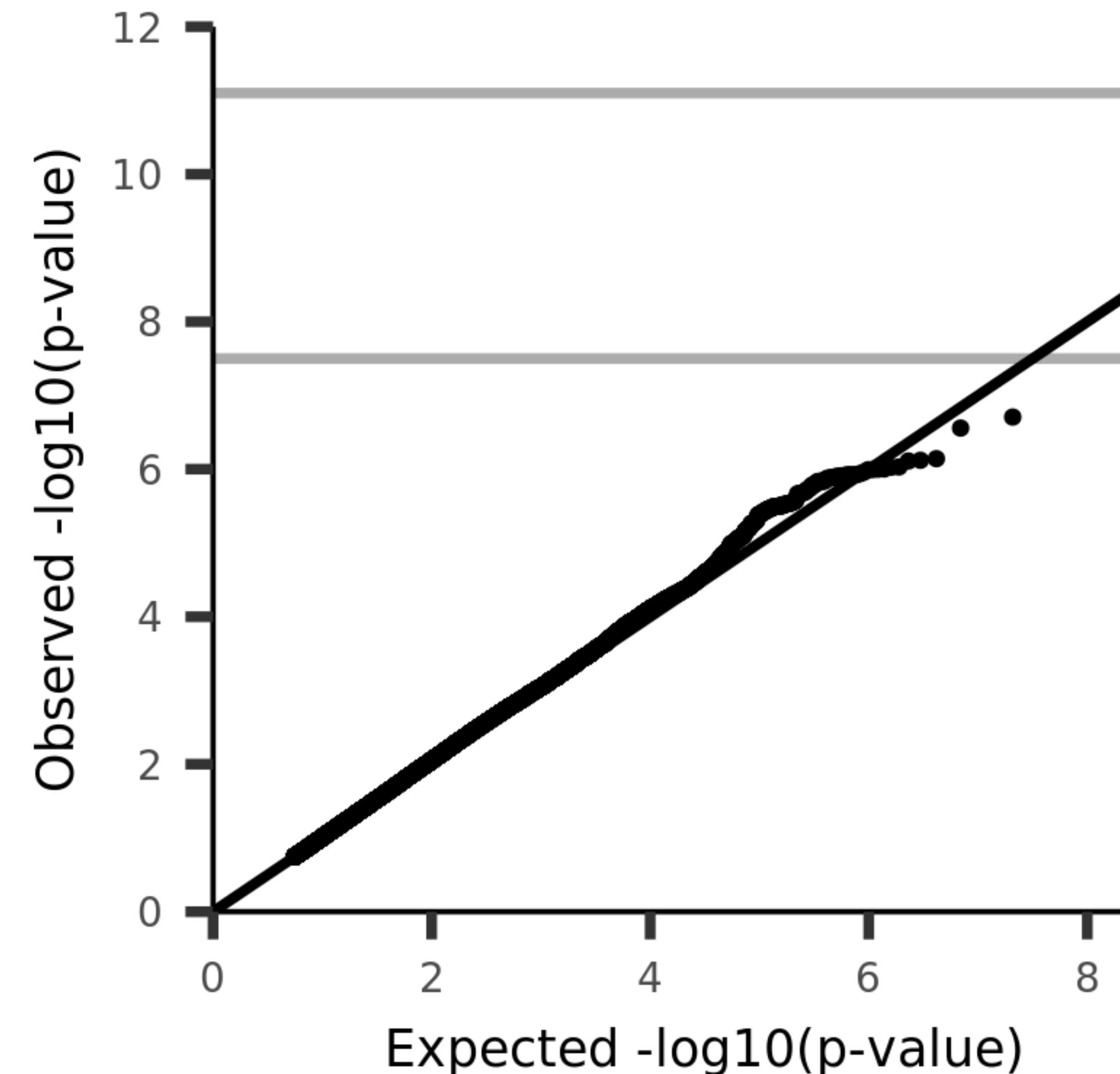
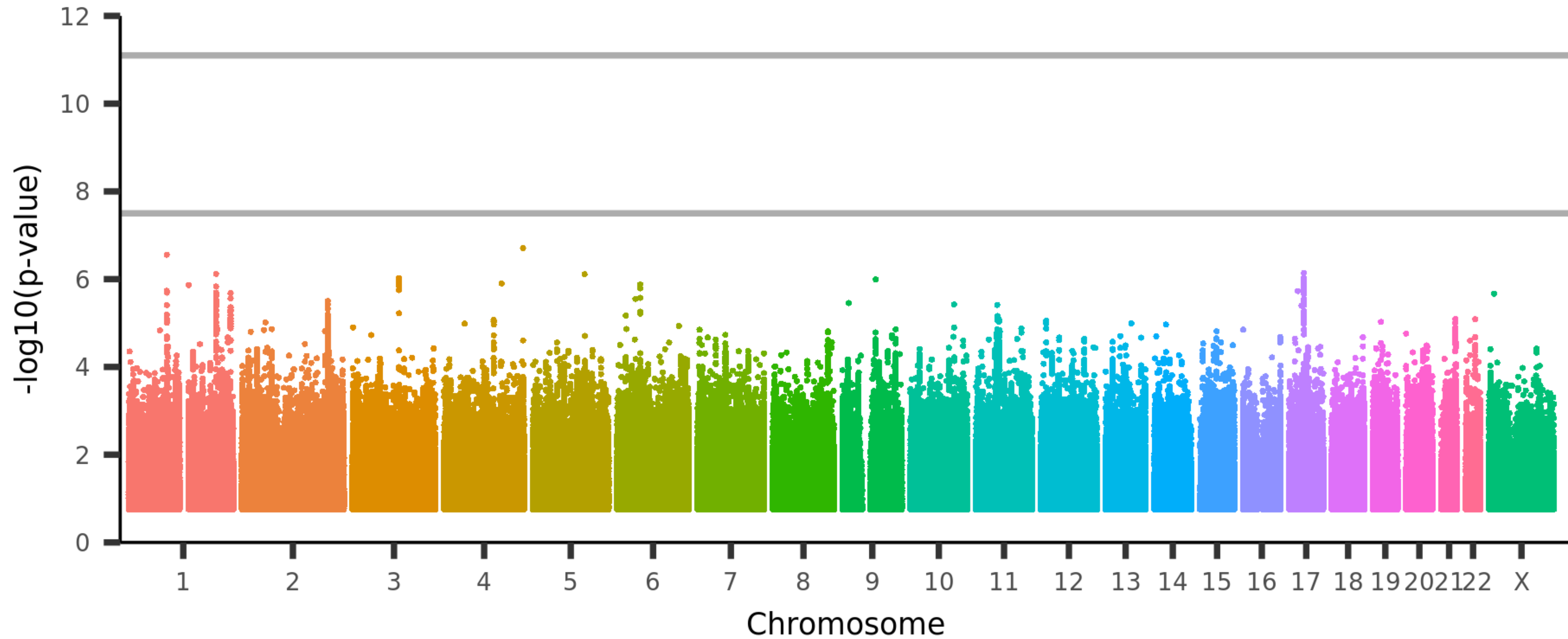


V1866



UKB_ID 25614, (IDP_dMRI_ProbtrackX_L2_ml_r)
Weighted-mean L2 in tract right medial lemniscus (from dMRI data)